



F 9

Experience in the surgical management of spontaneous spinal epidural hematoma

徐文慶

CHENG-CHIH LIAO, M.D., SHIH-TSENG LEE, M.D., WEN-CHIN HSU, M.D., LI-RONG CHEN, M.D., TAI-NGAR LUI, M.D., AND SAI-CHEUNG LEE, M.D.

Departments of Neurosurgery and Diagnostic Radiology, Chang Gung University and Chang Gung Memorial Hospital; and Department of Physical Medicine and Rehabilitation, Taoyuan General Hospital, Taoyuan, Taiwan

Object. Spontaneous spinal epidural hematoma (SSEH) is a rare disease entity. Although many cases have been reported in the literature, controversy persists as to its origin, diagnosis, and timing of treatment. The authors conducted a study in patients treated in their hospital and report the results.

Methods. Clinical data obtained in 35 patients with SSEH were retrospectively reviewed. Age, sex, history of hypertension, and history of anticoagulation therapy were recorded, and data were analyzed to clarify the possible predisposing factors of SSEH. Neurological outcomes were reappraised using a standardized grading system and correlated with the time interval from initial ictus to surgery, duration of complete neurological deficits, and the rapidity of deterioration of paralysis. Nonparametric methods and Spearman rank-correlation coefficients were used for statistical analysis.

Conclusions. Surgery is a safe and effective procedure to treat SSEH. The disease-related mortality rate was 5.7%, the surgery-related complication rate was 2.9%, and there were no operation-related deaths. Neurological outcome after surgery is positively correlated with preoperative neurological deficits (88.9% complete recovery in patients with incomplete neurological deficits compared with 37.5% in those with complete deficits [$p < 0.001$]). In patients in whom the time interval from initial ictus was shorter (< 48 hours) and in whom the duration of complete neurological symptoms was also briefer (< 12 hours), there is a positive correlation with better neurological and functional recovery ($p < 0.05$).

KEY WORDS • spontaneous epidural hematoma • functional recovery • neurological function

SPONTANEOUS spinal epidural hematoma is an uncommon but disabling disease entity. Holtas, et al.,²⁰ estimated the incidence of SSEH to be 13 individuals in a population of 1.49 million, or 0.1 patients per 100,000 individuals. Although approximately 400 cases have been reported in the literature,^{11,14,15,24,26} operative series with long-term clinical follow-up data remain few.^{16,22,35} The classic symptoms of SSEH are usually initiated with acute back or neck pain around the involved vertebrae with pain radiating to the corresponding dermatomes. The signs and symptoms of rapidly evolving neural element compression develops minutes to days later. If left untreated, frequently complete and permanent neurological deficits can occur and death has been occasionally reported.²⁶ Although cases of successful nonoperative treatment have been reported, rapid diagnosis and prompt extirpation of the spinal epidural clot remain the standard management.¹⁵ Previous surgical reports, however, usually lack standard documentation of long-term neu-

rological results,^{16,35} or they are based on a heterogeneous patient population that might bias the statistical analysis.²² In the present study we reviewed the management-related data obtained in patients with SSEH treated at our institution. We analyzed preoperative clinical presentations with associated predisposing factors as well as the relationships between the preoperative time intervals and postoperative results. The purpose of this study was to provide more sufficient information to clarify this surgically curable disease.

Clinical Material and Methods

The charts and radiographs of patients with epidural spinal hematoma treated in the neurosurgical department of Chang Gung Memorial Hospital during a recent 17-year period were retrospectively reviewed. The definition of nontraumatic spinal epidural hematoma proposed by Lonjon, et al.,²⁴ was used to select and homogenize the patient population. Cases involving spinal hematomas developing after vertebral trauma or after iatrogenic procedures were not included in the study. Thirty-five patients (26 males and nine females) met all criteria and form the basis of this study. The size of SSEH was con-

Abbreviations used in this paper: ASIA = American Spinal Injury Association; CI = confidence interval; CT = computerized tomography; MR = magnetic resonance; mRS = modified Rankin Scale; SSEH = spontaneous spinal epidural hematoma.

Spontaneous spinal epidural hematoma

sidered to comprise the number of vertebral segments it spanned. The distribution of SSEHs was divided into cervical, cervicothoracic, thoracic, thoracolumbar, and lumbar areas. Diagnosis of SSEH was confirmed by intraoperative and pathological examinations. To define the predisposing factors of SSEH, attention was paid to any action associated with straining during the initial onset of symptoms, including defecation, voiding, vomiting, sneezing, coughing, Valsalva maneuver, lifting objects, bending the body forward, and turning while in bed. Blood pressure rates were recorded in the emergency department and during the postoperative course; however, only in the latter was the measurement considered meaningful for diagnosis of hypertension. A diagnosis of hypertension was based on the following criteria: systolic/diastolic blood pressure at least 140/90 mm Hg or the need for antihypertension drugs.²¹

Neurological Recovery

Neurological recovery was reappraised using the five-tiered ASIA grading system.²⁸ Motor status was recorded at the time of surgery and at 1 month, 3 months, 6 months, and 1 year postoperatively. For the purpose of statistical analysis, the alphabetical ASIA scores were assigned numerical grades: A, 1; B, 2; and so on. The SSEH-related mortality was assigned a grade of 0, and was incorporated into alphabetical ASIA scores for statistical analysis. The mRS (Table 1) was used to evaluate the postoperative functional status.⁴⁰ In cases receiving an mRS score of 0, 1, or 2, the patients were considered to have made a functional recovery.

Statistical Analysis

Statistical analyses were performed using a commercially available software package. Nonparametric tests were used to analyze the correlations between the variables of the characteristics of patients or SSEH, preoperative time interval of symptoms, and the surgery-related outcome (ASIA grades) at 1, 3, 6, and 12 months postoperatively. For all statistical tests, a probability value less than 0.05 (two-tailed) was considered significant.

Results

Patient Population and Presentations of SSEH

Thirty-five (26 male and nine female) patients fulfilled the criteria of SSEH; their ages ranged from 7 months to 77 years (mean age 42.6 ± 3.8 years) (Fig. 1). In 12 patients (34.3%) hypertension was documented in the emergency department, whereas postoperative hypertension was documented in only seven patients (20%). One patient (2.9%) took warfarin (10 mg/day) to prevent thrombosis of the artificial aortic valve and the international normalized ratio for prothrombin time was 1.94 in the emergency department after SSEH. Three patients (8.4%) received low-dose (100 mg/day) aspirin for a remote cerebrovascular accident or myocardial infarction. Only one patient (2.9%) suffered mild thrombocytopenia ($102 \times 10^3/\text{dl}$) in the emergency department, but platelet count spontaneously recovered to $200 \times 10^3/\text{dl}$ 1 week postoperatively. Nineteen patients (54%) experienced subjective straining-associated events

TABLE 1
Summary of the mRS

Score	Description
0	no symptoms
1	no significant disability despite symptom: able to perform all usual duties & activities
2	slight disability: unable to perform all previous activities; able to care for own affairs w/o assistance
3	moderate disability: requires some help, but able to walk w/o assistance
4	moderately severe disability: unable to walk w/o assistance or attend to bodily needs
5	severe disability: bedridden, incontinent, & requires constant nursing care & attention

during the initial symptom attack. Thirty-three patients (94%) experienced sudden-onset back or neck pain including a 7-month-old infant, who presented with irritable crying, and a 2-year-old child, with tonic posture when turning the head to the left. The other two patients (5.7%) with lumbar SSEH suffered sudden focal muscular weakness after chronic low-back pain. The orientations of the SSEHs included five anterior (14.3%), three lateral (8.6%), nine posterolateral (25.7%), and 18 hematomas posterior to the dural sac (51.4%). Overall the SSEHs extended over one to 10 vertebral segments (median four segments [95% CI 3.36–4.63 segments]) (Table 2). Table 3 provides a summary of the SSEH-involved areas and associated clinical neurological presentations. Figure 2 provides a graphic representation of all involved segments. Preoperative deficits were incomplete in 18 patients (51.7%) and complete in 17 (48.3%). Preoperative ASIA grades and neurological deficits are summarized in Table 4. In each patient with incomplete neurological deficits, the power of portions of key muscles was no greater than Grade 2 and the duration of symptoms ranged from 10 hours to 1 month.

Radiological Diagnosis

Before 1994, SSEHs were diagnosed in five patients by myelography and in 12 patients by postmyelography CT scanning. After 1994, MR imaging was used to establish a diagnosis in 18 patients. In 12 cases myelography demonstrated complete block of contrast at the lowest level of

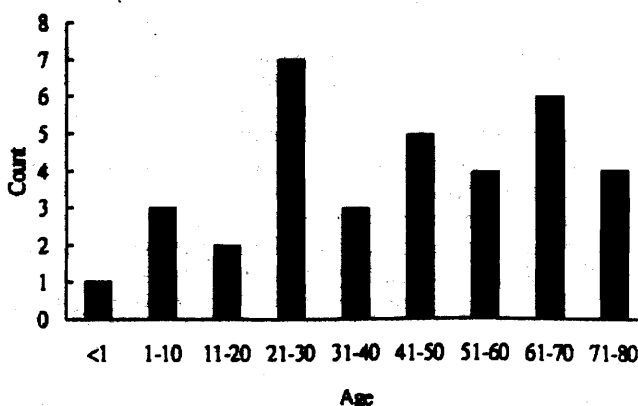


FIG. 1. Bar graph demonstrating distribution of age (in years) of 35 patients with SSEH.

TABLE 2
Demographic data and the location of SSEH in 34 patients

Variable	Location of SSEH					Total
	Cervical	Cervicothoracic	Thoracic	Thoracolumbar	Lumbar	
male/female	5:4	6:2	8:1	4:2	3:0	26:9
age (yrs)*	49.3 ± 19.8	28.7 ± 28.5	32.8 ± 14.2	54.7 ± 15.8	65.3 ± 10.8	46.6 ± 22.5
segments*	3.8 ± 1	5.9 ± 2.5	3.3 ± 1	3.7 ± 1	2 ± 1	4.0 ± 1.8
hypertension	3	1		2	1	7
anticoagulant		1				
antiplatelet	1			1	1	3

* Values are expressed as the means ± standard deviations.

SSEH, and in five it revealed spindle-shaped epidural filling defects. On postmyelography CT scans of the spine, SSEHs were demonstrated as intracanal soft-tissue densities that were relatively hyperintense to spinal cord and hypointense to the contrast medium. On all MR images, the SSEH appeared as a spindle-shaped intracanal space-occupying soft-tissue mass. Compared with myelography and CT scanning, the MR imaging was able to delineate the full extent of the epidural clot, except in the 2-year-old child in whom the SSEH extended from C-2 to T-4. Neurological recovery in patients with MR imaging–documented diagnoses, however, was not significantly different from that in those with CT myelography– or myelography alone–based diagnoses (Mann–Whitney U-test, $p = 0.26$). On T_1 -weighted MR images, the SSEH signals were homogeneously isointense to the spinal cord in 15 patients (Fig. 3) and hyperintense in five patients (Fig. 4). On T_2 -weighted images, SSEH signals showed heterogeneous intensity: 16 primarily hyperintense, one isointense, and one hypointense to the spinal cord. After Gd administration, peripheral enhancement surrounding the clot was demonstrated in four cases, in none of which was enhancement homogeneous or intense. On T_2 -weighted images obtained in eight patients, we observed hyperintense signal in the compressed spinal cord representing intramedullary edema (Fig. 4). Four (50%) of the eight patients with cord edema and one (10%) of the 10 without cord edema did not experience functional recovery by the time of the last recorded examination. Although neurological recovery seemed poorer in the patients in whom there was an intramedullary hyperintense signal on T_2 -weighted images, the difference was not significant to draw a conclusion about the relationship between cord edema and poor neurological recovery (Fisher exact test, $p = 0.12$). Four patients underwent angiography. In one case angiography was performed before the operation because frequent fluctuations of complete neurological deficits were followed by rapid recovery in 3 days, which made physicians suspect the possibility of vascular lesion. Three patients underwent postoperative angiography because difficult hemostasis was noted intraoperatively. In all cases, however, the tests proved negative for vascular anomalies.

Surgical Treatment and Outcome

One patient did not undergo the operation, and his data were excluded from the analysis of surgical outcome. He recovered from the 4-hour-duration complete spinal cord dysfunction spontaneously, and follow-up MR imaging

performed 5 days after symptom onset revealed that the thoracic SSEH had resolved. In the five cases of anteriorly located SSEHs, one patient underwent anterior cervical disectomy and evacuation of the short clot at C5–6, but the remaining four required laminectomy because the clots covered several segments (three–six levels) and were located in the thoracolumbar region, which made an anterior approach difficult. The remaining 29 patients underwent laminectomy for evacuation of the posterior or lateral epidural clots. The follow-up period ranged from 3 months to 15 years (mean 4.32 ± 0.59 years). There was neither surgery-related death nor recurrent hematoma. A surgery-induced complication of wound disruption occurred in a 2-year-old boy (2.9%), but the neurological outcome was excellent 6 months after the operation (from an ASIA grade of A to one of E). The interval between symptom onset (pain and/or neurological deficit) to operation ranged from 10 hours to 2 months (median 28 hours [95% CI 50.3–292.6 hours]). Neurological status deteriorated to a steady state over variable periods of time: minutes to 2 hours in 18 patients, 2 to 24 hours in nine patients, and longer than 24 hours in seven patients. The preoperative duration of maximal neurological deficits ranged from 0 hours (symptom in progression) to greater than 1 month (median 12 hours [95% CI 13.7–93.7 hours]). In the 18 surgically treated patients with incomplete neurological deficits, status in 14 (77.8%) recovered to an ASIA grade of D within 1 month after operation, in 16 (88.9%) to a grade of E within 1 year, and all patients by the time of last recorded follow up (mean 4.03 ± 3.48 years). In 16 surgically treated patients with complete neurological deficits, status in six patients (37.5%; five by 1

TABLE 3
The location of SSEHs and related preoperative neurological deficits

Involved Area	Myelopathy	Hemiplegia	Brown–Séquard	Radiculopathy or Cauda Equina	Total
cervical	4	4	1		9
cervicothoracic	7		1		8
thoracic	9*				9
thoracolumbar	6				6
lumbar	1			2	3
total	27*	4	2	2	35*

*Including the patient with spontaneous recovery in hours without operative treatment.

Spontaneous spinal epidural hematoma

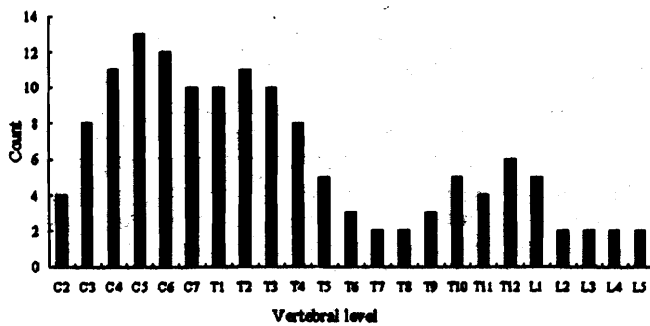


Fig. 2. Bar graph showing distribution of involved segments of SSEH in 35 patients.

year and one by 2 years) recovered to an ASIA grade of E after a mean follow-up period of 4.88 ± 3.46 years (Table 5). The follow-up periods of patients with complete and incomplete preoperative neurological deficits were not significantly different (Mann-Whitney U-test, $p = 0.4$). Neurological recovery in patients with incomplete preoperative deficits, however, was significantly better than that in those with complete deficits (Mann-Whitney U-test, $p < 0.001$).

In patients with complete preoperative neurological deficits, three time factors (interval from initial onset to operation, rate of symptom progression, and duration of maximal deficits) were analyzed with the final surgery-related outcomes in terms of the ASIA grading system. There was no correlation between outcome and the rate of symptom progression. The interval between initial onset to operation and the duration of maximal deficits were inversely correlated with the final neurological recovery reflected by ASIA grades (Spearman rank-correlation coefficients -0.519 and -0.723 , with $p = 0.04$ and 0.002 , respectively). Among the 12 patients who underwent surgery within 48 hours after the initial onset of symptoms, status in six patients recovered to an ASIA grade of E, in three to one of D, in two to one of C, and in only one did it remain at a grade of A at the censoring time (mean follow up 5.24 ± 3.25 years). By comparison, of the four patients who underwent surgery 48 hours after the initial symptom onset, two died and two remained completely paralytic (ASIA Grade A) after 6- and 8-year follow up, respectively. Furthermore, the median ASIA grades (at 1, 3, 6, and 12 months postoperatively) were significantly higher in the 12 patients who underwent surgery within 48 hours than in the four patients in whom the operation was performed after 48 hours (Fig. 5 upper [Mann-Whitney U-test, $p < 0.005$]). Of the eight patients in whom complete neurological deficits lasted less than 12 hours preoperatively, status in five recovered completely within 1 year, in two it recovered to an ASIA grade of D at censoring time, with follow-up periods of 3 and 6 months, respectively, and one patient remained completely paralytic (mean follow up 4.71 ± 3.5 years). In the eight patients with preoperative complete paralysis lasting more than 12 hours, status in one recovered completely (ASIA Grade E); functional recovery occurred in one, though spastic gait remained (ASIA Grade D); nonfunctional recovery occurred in two in whom muscle strength in half

TABLE 4

Preoperative neurological deficits and the related ASIA grades

Preop ASIA Grade	Myelopathy	Hemiplegia	Brown-Séquard	Radiculopathy or Cauda Equina	Total
A	17*				17*
B	3				3
C	5	3			8
D	2	1	2	2	7
total (%)	27 (77)*	4 (11.4)	2 (5.7)	2 (5.7)	35*

* Includes the one case in which neurological deficits recovered spontaneously without operation.

of the key muscles was less than Grade 3 (ASIA Grade C); and no recovery was observed in four (ASIA Grade A) including death in two cases (mean follow up 5.05 ± 3.07 years). Therefore, more rapid recovery and better neurological outcome were observed in surgically treated patients in whom the duration of deficits was 12 hours or less (Fig. 5 lower [Mann-Whitney U-test, $p < 0.005$]).

Two patients with preoperative complete deficits and one with an incomplete deficit were dead at the censoring time. The first patient with cervical SSEH died of aspiration pneumonia 4 months after the operation, and the second patient, who was receiving anticoagulant therapy for pacemaker insertion, died of pacemaker-related dysfunction 3 weeks after the operation. In both cases the patients did not recover from the complete neurological dysfunction, and the causes of death were considered related to SSEH. The third case was a 73-year-old woman in whom SSEH spanned from C2-5 and who presented with right hemiparesis (her worst muscle strength was Grade 2, lasting for 1 week). After evacuation of the clot, her status recovered to an ASIA grade of D by 1 month. She died, however, of recurrent strokes 3 years after the SSEH surgery. It was thought that the death was not related to SSEH, and the neurological recovery was coded as ASIA Grade D for analysis. In addition to the third case, a 74-year-old woman with preoperative incomplete deficits did not experience complete recovery postoperatively. On MR imaging of the lumbar spine the T12-L4 SSEH demonstrated an intramedullary hyperintense signal of the conus medullaris. Twelve hours after developing paralysis, she underwent evacuation of the clot, and chronic liquefied dark blood was found intraoperatively. The strength of the L-5 and S-1 key muscles, however, remained Grade 2 at 2 years postoperatively. Vascular compromise presenting as hyperintense spinal cord signal may have been the cause of sudden paralysis in the patient. Pathological examinations of specimens obtained in 34 patients showed blood clotting. No vascular anomaly was found when the surgical specimen was microscopically reappraised. Six SSEHs in three previously reported cases were described as motor oil-like with fibrotic encapsulation, and the cases were considered to be chronic.²⁵ The chronic SSEHs involved the cervicothoracic region in one case, the thoracic region in two, the thoracolumbar spine in one, and the lumbar region in two; the final functional recovery was not related to the acute or chronic characteristics of clotting (Fisher exact test, $p = 1$).

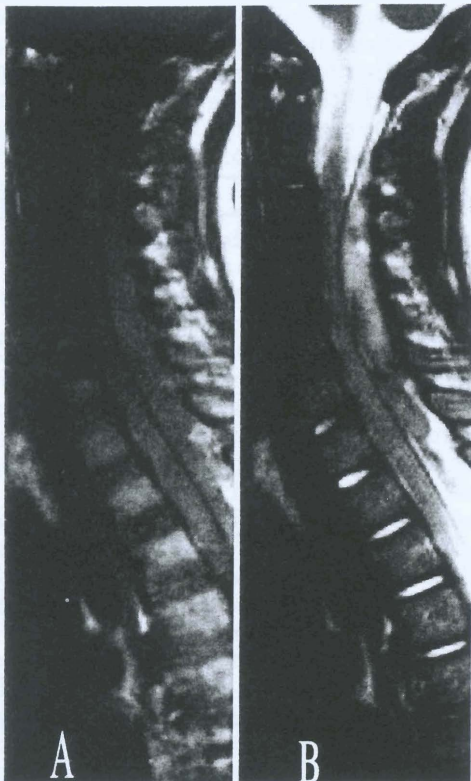


FIG. 3. Sagittal MR images obtained in a 2-year-old boy suffering from sudden-onset tonic head turning to the left and rapid sensorimotor paralysis (ASIA Grade A). A: A T₁-weighted image of the cervicothoracic spine revealed an isointense C2–T4 fusiform intraspinal lesion. B: A T₂-weighted image demonstrating that the lesion became primarily hyperintense to the spinal cord with foci of hypointensity. After complete neurological deficits persisted for 8 hours, the patient underwent laminectomy and evacuation of the intraspinal lesion, which was proven to be a fresh blood clot. Recovery was complete within 6 months. The SSEH had not recurred by the 3.5-year follow-up examination.

Discussion

Origins of SSEH

Neither the cause nor pathogenesis of spontaneous epidural hematoma is currently clear. Miscellaneous factors such as hypertension,¹ ingestion of anticoagulant agents,^{17,27} straining, sneezing, lifting, and spinal vascular anomaly^{13,19,23,36} have been hypothesized to predispose to this disease. In the present study, the incidences of hypertension in SSEH patients were 34.3% in the emergency department and 20% in the postoperative ward, which are values that are not different from the prevalence in the adult population in Taiwan (26% in males and 19% in females).³² Therefore, it is presumed that hypertension may coincidentally occur with SSEH rather than being a predisposing factor of SSEH, especially given the stressful condition initiated by the symptomatic pain followed by progressive sensorimotor paralysis. With regard to the role of anticoagulant therapy in the genesis of SSEH, a causal relationship cannot be established because only a small incidence of SSEH was related to the ingestion of warfarin (2.9%) and aspirin (8.4%), and in no case in the present study was there evi-

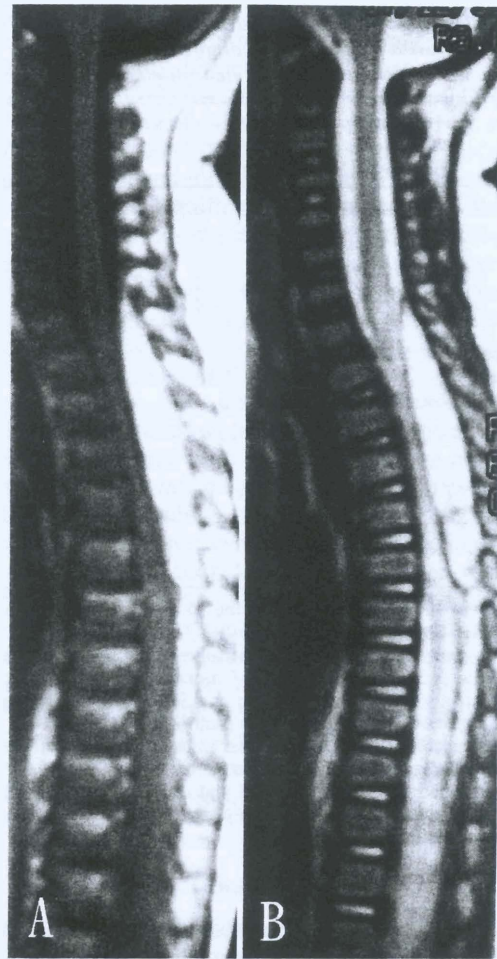


FIG. 4. Sagittal MR images obtained in a 6-month-old girl who experienced complete paraplegia 2 hours after an episode of upper-respiratory tract infection with fever and cough. She was treated for Guillain-Barré syndrome in a pediatric department for more than 1 week before cervical MR imaging was performed. The cervicothoracic images revealed a hyperintense C7–T7 fusiform lesion on both T₁- (A) and T₂-weighted (B) images with marked spinal cord compression. The intramedullary hyperintense signal on T₂-weighted images represented spinal cord edema and possible infarction. Although she underwent evacuation of the lesion, she remained completely paraplegic with autonomic dysfunction 7.5 years after operation.

dence of bleeding diathesis during the onset. In addition, in millions of people receiving anticoagulant drugs, the worldwide prevalence of SSEH supports no significant causative factor.⁵

Although the authors of some reports have provided convincing radiological or histological evidence that extradural spinal vascular anomaly results in SSEH,^{9,14,30} no such cases were identified in the present study. It could only be concluded that a vascular anomaly may be an exceptional cause of SSEH. Based on their observation of rapidly evolving signs of SSEH-induced spinal cord compression and based on the fact that the low-pressure epidural veins can be easily tamponaded by normally expanded dural sac during some surgeries, Beatty and Winston³ assumed that the disruption of small epidural arteries might cause SSEH.

Spontaneous spinal epidural hematoma

TABLE 5

Cumulative postoperative neurological outcomes in 16 patients with preoperative complete and 18 patients with incomplete neurological deficits

ASIA Grade	Mos After Op					Censoring Time
	Op	1	3	6	12	
cases w/ complete deficit*						
A	16	5	4	4	4	4
B						
C		2	2	1	1	1
D		9	9	5	2	2
E				3	5	5
dead			1	2	2	2
total	16	16	16	15	14†	16
cases w/ incomplete deficits‡						
A						
B	3					
C	8					
D	7	14	11	5	2	2
E		4	7	13	15	16
dead						
total	18	18	18	18	17§	18

* The mean follow-up period in the 16 patients with preoperative complete deficits was 4.88 ± 3.46 years.

† Two patients had not undergone follow up to 1 year by the censoring time (one for 3 months and one for 6 months). Both, however, could walk independently, recovery was coded as ASIA Grade D, and functional recovery was considered complete in each.

‡ The mean follow-up period in the 18 patients with preoperative incomplete deficits was 4.03 ± 3.48 years.

§ One patient with lumbar SSEH and intractable sciatica was followed up for 6 months. He recovered completely within 1 week after laminectomy and evacuation of SSEH.

Gundry and Heithoff¹⁶ reported on 18 patients, seven (39%) of whom harbored an associated herniated disc, and they hypothesized that the herniated disc might tear the fragile epidural veins of Batson and cause epidural clotting. Anteriorly located SSEH, however, is relatively rare in other published reports^{4,15,27} and the present study. Therefore, the hypothesis proposed by Grundy and Heithoff cannot explain the pathogenesis in the majority of SSEHs located posteriorly to the sac. Cooper⁸ and Markham, et al.,²⁶ noted that the onset of SSEH-related symptoms was usually caused by insignificant straining efforts; we found this to be so in 19 patients (54%) in our study. Cooper and Markham, et al., presumed that the pathophysiological mechanism might involve the transmission of intraabdominal or thoracic pressure to the epidural venous plexus during those maneuvers. Because these insignificant physiological processes are numerous in daily life and because relative development of SSEH in these straining-associated activities is rare, a causal relationship cannot be realistically established. It is suggested that the pathogenesis of SSEH may be multifactorial and need further evidence to clarify its real origin.

Diagnosis of SSEH

The clinical presentation of SSEH has been well described by Bruyn and Bosma:⁵ a sudden onset of back or neck pain that radiates to corresponding dermatomes and which is followed by signs of nerve root or spinal cord compression. They also described detailed clinical evalu-

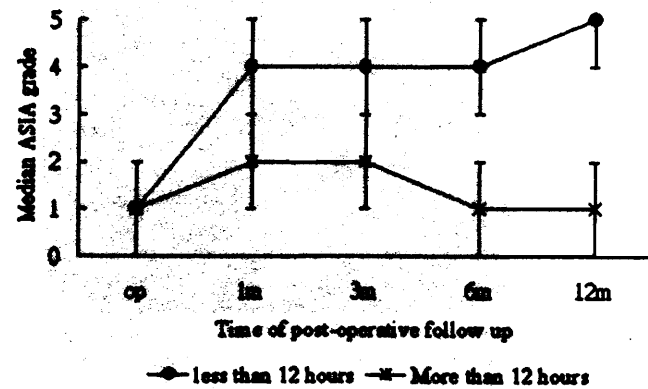
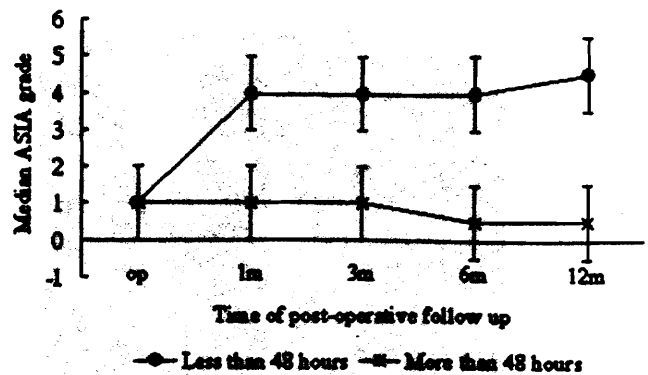


FIG. 5. Graphs showing the plots of median ASIA grades at 1, 3, 6, and 12 months postoperatively. Grades were converted into numerical equivalents (A, 1; B, 2; and so on). Death is indicated by a grade of 0. Upper: Outcome is significantly better in patients undergoing surgery within 48 hours after the initial symptom onset (Mann-Whitney U-test, $p < 0.05$). Lower: Better outcomes occurred in patients in whom the maximal duration of deficits was less than 12 hours (Mann-Whitney U-test, $p < 0.05$).

ations with symptoms and signs to differentiate miscellaneous lesions simulating SSEH. In view of acute deterioration of neurological deficits, pathological entities associated with spinal cord compression need to be evaluated with myelography, spinal CT scanning, or MR imaging as soon as possible.^{3,6,19,20} Although myelography can demonstrate signs of compression—with visualization of non-specific contrast blockage or extradural convex compression—it cannot be used to determine the nature and the real extension of the lesion.^{8,10,33} Combined with spinal CT scanning, SSEH can be viewed as an intraspinal biconvex and hyperdense lesion with the density equivalent to blood.^{3,34} Spinal CT scanning, however, may be nondiagnostic in the thoracic spine where resolution is poorer than in the lumbar and cervical spine because of the high contrast between the lung parenchyma and vertebral bone.² Therefore, in the modern era, myelography and CT scanning have been replaced by MR imaging, which provides a noninvasive and clear view of the precise location of the lesion, its position, size, probable nature, and the degree of cord compression. On T₁-weighted imaging, SSEH usually displays isointense signal to the spinal cord within 24

hours after symptom onset and hyperintense signal to the cord after 36 hours.^{4,6,7} Holtas, et al.,²⁰ have suggested that the signal shift from early-stage isointensity to intermediate-stage hyperintensity on T₁-weighted MR images could be pathognomonic for diagnosis of SSEH. Fukui, et al.,¹² however, did not find this to be universally true in their series in which SSEH-related isointensity persisted up to 5 days after symptom onset. In addition, SSEH often causes rapid neurological deterioration, and the lesion is frequently evacuated rapidly after the initial studies. Thus, the MR imaging signal shift demonstrated on the sequential T₁-weighted MR images may only be useful in the follow-up evaluation of conservatively treated cases and is not practical in surgery-treated patients. In all previous reports and this study, T₂-weighted imaging demonstrated that almost all SSEH displayed a primary hyperintensity with hypointense foci. Its specific appearance on T₂-weighted images would provide more characteristic information for diagnosis, especially when the characteristic signal shift on T₁-weighted images is lacking during the acute status. Furthermore, its specific T₂-weighted signals also aid in the differentiation of epidural blood clot from spinal epidural tumor as metastasis or lymphoma that may display the misleading SSEH-related isointense signal on the T₁-weighted images.¹² In this study, T₂-weighted imaging also revealed increased intensity of the compressed spinal cord, which implied the development of spinal cord edema or ischemia (Fig. 4). In eight patients with spinal cord edema, functional recovery failed in four (50%) compared with the 10 patients without cord edema in whom functional recovery occurred in all but one (10%). Magnetic resonance imaging with T₂-weighted sequences is potentially useful for predicting the neurological outcome in patients with SSEH; this can be judged by the intramedullary hyperintensity representing spinal cord ischemia. This finding, however, may be due to the small case numbers, because statistical significance was not reached ($p = 0.12$).

Management and Outcomes of SSEH

In view of the numerous reports, SSEH remains a rare and unfamiliar clinical entity. Pathologically, its clinical manifestation results from an expanding intraspinal space-occupying lesion resembling the experimental model of gradual spinal compression performed by Tarlov.³⁸ He demonstrated that dogs with complete hindlimb paralysis could only recover after decompression when the time interval was less than 9 hours. Results in one of our patients and in dozens reported in the literature suggest that favorable outcomes may be achieved without operations when the symptoms were mild and could improve spontaneously after a few hours.^{4,12,17,18,31,37,41} In cases in which the SSEH did not disappear spontaneously in time, or in those in which symptoms actively deteriorated spinal cord decompression should be performed as soon as possible to cure the spinal dysfunction.^{11,22,29,39} In a review of 333 patients with SSEH, Groen and Van Alphen¹⁵ concluded that surgical evacuation of SSEH within 36 hours in cases involving complete spinal dysfunction and within 48 hours in those involving incomplete deficits resulted in favorable outcomes. In the present study of 34 surgical cases, preoperative status remained the most critical factor to determine

postoperative neurological recovery. In patients with incomplete preoperative neurological deficits, the recovery rate of normal sensorimotor function 1 year postoperatively was significantly higher than in those with complete deficits (88.9 and 37.5%, respectively; $p < 0.001$). Once preoperative neurological status deteriorated to complete sensorimotor and autonomic dysfunction (ASIA Grade A), patients who underwent surgery within 48 hours of pain onset experienced significantly better recovery than those surgically treated more than 48 hours after symptom onset, as demonstrated at 1, 3, 6, and 12 months postoperatively ($p < 0.005$). Similarly, better results were observed in patients who underwent surgery when the duration of neurological dysfunction was less than 12 hours compared with more than 12 hours ($p < 0.005$).

In our analysis, age, sex, location or extension of the SSEH, and the rate of evolution of symptoms and signs of SSEH-induced spinal cord compression were not correlated with the postoperative neurological outcomes. It is difficult, however, to establish the absolute time limit to ensure complete neurological recovery because some neurological recoveries occurred considerably longer after surgical intervention. Although the actual force and time interval required to produce symptomatic SSEH-induced spinal cord compression may never be established, we suggest that the SSEH can be viewed as a clinical model that gradually causes spinal cord compression, as in the dog model proposed by Tarlov,³⁸ and furthermore that it should be treated by aggressive and emergency decompressive surgery at once if complete neurological deficits ensue.

Conclusions

Spontaneous spinal epidural hematoma is a rare but disabling surgical disorder. Its origin is scarcely correlated with hypertension, anticoagulation therapy, and extradural spinal vascular anomaly. Although this could not be proven based on current evidence, shifting of intrathoracic or intraabdominal pressure during some physiological exercise may rupture the epidural venous plexus and result in epidural hematoma. Sudden onset of back or neck pain followed by rapid sensorimotor paralysis due to hematoma-induced compression of the spinal cord or nerve roots is a well-documented and typical presentation. Prompt MR imaging examination can delineate the intraspinal lesions in patients with acute spinal cord compression syndrome. Furthermore, T₂-weighted MR imaging provides additional information to determine the nature of SSEH. Surgery is a safe, effective, and indispensable method of treating the disease, with a related complication rate of 2.9%. Although the SSEH-related mortality rate was 5.7% in the present series, there was no operation-related fatality. One hundred percent functional recovery and 88.9% complete neurological recovery were achieved in patients with preoperative incomplete neurological deficits. The result is significantly better than that in patients with preoperative complete neurological deficits (complete neurological recovery rate 37.5%; $p < 0.001$). In patients with complete (ASIA Grade A) deficits, good neurological recovery can also be achieved after timely surgery when the interval between the initial ictus (mostly pain) and surgery is less than 48 hours and when

Spontaneous spinal epidural hematoma

the durations of the complete neurological deficits is less than 12 hours.

References

1. Ainslie JP: Paraplegia due to spontaneous extradural or subdural hemorrhage. *Br J Surg* 45:565-567, 1958
2. Avrahami E, Tadmor R, Ram Z, et al: MR demonstration of spontaneous acute epidural hematoma of thoracic spine. *Neuroradiology* 31:89-92, 1989
3. Beatty RM, Winston KR: Spontaneous cervical epidural hematoma. A consideration of etiology. *J Neurosurg* 61:143-148, 1984
4. Boukobza M, Guichard JP, Boissonet M, et al: Spinal epidural haematoma: report of 11 cases and review of the literature. *Neuroradiology* 36:456-459, 1994
5. Bruyn GW, Bosma NJ: Spinal extradural hematoma, in Vinken PJ, Bruyn GW (eds): *Handbook of Clinical Neurology*. Amsterdam: North-Holland Publishing, 1976, pp 1-30
6. Carlier R, Engerand S, Lamer S, et al: Foraminal epidural extraosseous cavernous hemangioma of the cervical spine: a case report. *Spine* 25:629-631, 2000
7. Chen CJ, Hsu WC: Imaging findings of spontaneous spinal epidural hematoma. *J Formos Med Assoc* 96:283-287, 1997
8. Cooper DW: Spontaneous spinal epidural hematoma. Case report. *J Neurosurg* 26:343-345, 1967
9. D'Angelo V, Bizzozero L, Talamonti G, et al: Value of magnetic resonance imaging in spontaneous extradural spinal hematoma due to vascular malformation: case report. *Surg Neurol* 34:343-344, 1990
10. Dawson BH: Paraplegia due to spinal epidural hematoma. *J Neurol Neurosurg Psychiatry* 26:171-173, 1963
11. Foo D, Rossier AB: Preoperative neurological status in predicting surgical outcome of spinal epidural hematomas. *Surg Neurol* 15:389-401, 1981
12. Fukui MB, Swarnkar AS, Williams RL: Acute spontaneous spinal epidural hematomas. *AJNR Am J Neuroradiol* 20:1365-1372, 1999
13. Graziani N, Bouillot P, Figarella-Bragner D, et al: Cavernous angiomas and arteriovenous malformations of the spinal epidural space: report of 11 cases. *Neurosurgery* 35:856-864, 1994
14. Groen RJ, Ponssen H: The spontaneous spinal epidural hematoma. A study of the etiology. *J Neurol Sci* 98:121-138, 1990
15. Groen RJ, van Alphen HA: Operative treatment of spontaneous spinal epidural hematomas: a study of the factors determining postoperative outcome. *Neurosurgery* 39:494-509, 1996
16. Gundry CR, Heithoff KB: Epidural hematoma of the lumbar spine: 18 surgically confirmed cases. *Radiology* 187:427-431, 1993
17. Harik SI, Raichle ME, Reis DJ: Spontaneous remitting spinal epidural hematoma in a patient on anticoagulants. *N Engl J Med* 284:1355-1357, 1971
18. Hernandez D, Viñuela F, Feasby TE: Recurrent paraplegia with total recovery from spontaneous spinal epidural hematoma. *Ann Neurol* 11:623-624, 1982
19. Hillman J, Bynke O: Solitary extradural cavernous hemangiomas in the spinal canal. Report of five cases. *Surg Neurol* 36:19-24, 1991
20. Holtas S, Heiling M, Lonntoft M: Spontaneous spinal epidural hematoma: findings at MR imaging and clinical correlation. *Radiology* 199:409-413, 1996
21. Joint National Committee on Prevention, Detection, Evaluation, and Treatment of High Blood Pressure. National High Blood Pressure Education Program. Sixth report. Available at: <http://www.nhlbi.nih.gov/guidelines/hypertension/jncintro.html>
22. Lawton MT, Porter RW, Heiserman JE, et al: Surgical management of spinal epidural hematoma: relationship between surgical timing and neurological outcome. *J Neurosurg* 83:1-7, 1995
23. Lee JP, Wang AD, Wai YY, et al: Spinal extradural cavernous hemangioma. *Surg Neurol* 34:345-351, 1990
24. Lonjon MM, Paquis P, Chanalet S, et al: Nontraumatic spinal epidural hematoma: report of four cases and review of the literature. *Neurosurgery* 41:483-487, 1997
25. Lui TN, Lee ST: Chronic spontaneous spinal epidural hematoma. *J Surg Assoc ROC* 23:416-20, 1990
26. Markham JW, Lynge HN, Stahlman GE: The syndrome of spontaneous spinal epidural hematoma. Report of three cases. *J Neurosurg* 26:334-342, 1967
27. Mattie H, Sieb JP, Rohner M, et al: Nontraumatic spinal epidural and subdural hematomas. *Neurology* 37:1351-1356, 1987
28. Maynard FM Jr, Bracken MB, Creasey G, et al: International Standards for Neurological and Functional Classification of Spinal Cord Injury. American Spinal Cord Injury Association. *Spinal Cord* 35:266-274, 1997
29. McQuarrie IG: Recovery from paraplegia caused by spontaneous spinal epidural hematoma. *Neurology* 28:224-228, 1978
30. Olivero WC, Hanigan WC, McCluney KW: Angiographic demonstration of a spinal epidural arteriovenous malformation. Case report. *J Neurosurg* 79:119-120, 1993
31. Pahapill PA, Lownie SP: Conservative treatment of acute spontaneous spinal epidural hematoma. *Can J Neurol Sci* 25:159-163, 1998
32. Pan WH, Chang HY, Yeh WT, et al: Prevalence, awareness, treatment and control of hypertension in Taiwan: results of Nutrition and Health Survey in Taiwan (NAHSIT) 1993-1996. *J Hum Hypertens* 15:793-798, 2001
33. Pear BL: Spinal epidural hematoma. *Am J Roentgenol Radium Ther Nucl Med* 115:155-164, 1972
34. Post MJ, Seminer DS, Quencer RM: CT diagnosis of spinal epidural hematoma. *AJNR Am J Neuroradiol* 3:190-192, 1982
35. Rohde V, Küker W, Reinges MH, et al: Microsurgical treatment of spontaneous and non-spontaneous spinal epidural hematomas: neurological outcome in relation to aetiology. *Acta Neurochir* 142:787-793, 2000
36. Rosenblum B, Oldfield EH, Doppman JL, et al: Spinal arteriovenous malformation: a comparison of dural arteriovenous fistulas and intradural AVM's in 81 patients. *J Neurosurg* 67:795-802, 1987
37. Saito S, Katsube H, Kobayashi Y: Spinal epidural hematoma with spontaneous recovery demonstrated by magnetic resonance imaging. *Spine* 19:483-486, 1994
38. Tarlov IM, Herz E: Spinal cord compression studies. IV. Outlook with complete paralysis in man. *Arch Neurol Psychiatry* 72:43-59, 1954
39. Tarlov IM: Spinal cord compression studies. III. Time limits for recovery after gradual compression in dogs. *Arch Neurol Psychiatry* 71:588-597, 1954
40. van Swieten JC, Koudstaal PJ, Visser MC, et al: Interobserver agreement for the assessment of handicap in stroke patients. *Stroke* 19:604-607, 1988
41. Wagner S, Forsting M, Hacke W: Spontaneous resolution of a large spinal epidural hematoma. Case report. *Neurosurgery* 38:816-818, 1996

Manuscript received April 4, 2003.

Accepted in final form August 25, 2003.

Address reprint requests to: Shih-Tseng Lee, M.D., Department of Neurosurgery, Chang Gung Memorial Hospital, 5, Fu-shing Street, 333, Kweishan, Taoyuan, Taiwan. email: yun0710@adm.cgmh.org.tw.